

Cerebral Lipiodol® Embolism after interventional lymphatic embolization: a case report

Piet Waelkens M.D^{1*}, Sofian Bouneb M.D¹, Johan Vandommele M.D¹

Piet Waelkens M.D, Sofian Bouneb M.D, Johan Vandommele M.D. Cerebral Lipiodol® Embolism after interventional lymphatic embolization: a case report. *Anesthesiol Case Rep* 2020;3(2):1-3.

An infant with a medical history of an univentricular heart developed plastic fibrosis after a Fontan circuit correction. A lymphatic embolization was performed for symptomatic improvement. After one hour on the post-anesthesia care unit (PACU), the patients mental status altered and had

seizures. Neuroimaging revealed multiple hyper densities in the brain due to Lipiodol embolization. Cerebral Lipiodol embolism is a rare but potentially lethal complication following interventional lymphatic procedures. This case is unique due to its severity of the embolisms. Attention should be paid on postoperative neurological exam and prolonged PACU stay is advised.

Key Words: *Ethiodized oil, Intracranial embolism, Therapeutic embolization, Case reports*

GLOSSARY

EQUATOR: Enhancing the Quality and Transparency of Health Research; PACU: Post Anesthesia Care Unit; TCPC: Total Cavopulmonary Connection; SIRS: Systematic Inflammatory Response Syndrome

INTRODUCTION

Plastic bronchitis is characterized by an abnormal pulmonary lymphatic flow. Lymph drainage occurs via lymphatic channels to the lung and the pleural space [1]. The disease is caused by the formation of proteinaceous casts within the airways. Patients with congenital heart diseases are most affected, specifically patients with single ventricle physiology following the Fontan procedure. The incidence after total cavopulmonary connection (TCPC) is estimated to be 4% and mean mortality 33% [2].

Percutaneous lymphatic interventions are used for symptomatic improvement in both chylothorax and plastic bronchitis [3]. Initially, embolization of the thoracic duct was performed to avoid retrograde lymphatic flow from the thoracic duct towards lung parenchyma. A more targeted embolization of the lymphatic ducts is executed nowadays. Embolization is accomplished using Lipiodol, MReye® coils or glue. Other therapeutic options for plastic bronchitis consists of lowering the venous pressure and medical treatment with sildenafil, steroids and mucolytics. Heart transplantation can result in long term resolution.

Lipiodol is a mixture that contains 37% iodine and ethyl esters of the fatty acids of poppy seed oil [4]. It is frequently used as a radio-opaque contrast in lymphangiography and for trans catheter arterial chemoembolization of liver tumors. Extravasation of Lipiodol from lymph vessels into the venous system may cause Lipiodol embolism in the brain, lung and kidney.

We describe a child with congenital heart disease undergoing a lymphatic embolization for refractory chylous pleural effusions and plastic bronchitis. Written informed consent was obtained from the family of the patient for publication of this case report. This article adheres to the applicable Enhancing the Quality and Transparency Of health Research (EQUATOR) guideline.

CASE DESCRIPTION

An 11-year old boy with an univentricular heart due to an atrio-ventricular septum defect, which was corrected with a Glenn shunt and then followed

afterwards with a Fontan circulation, developed plastic bronchitis. Normal oxygen saturation was 92%. He had multiple pleural effusions after the Fontan operation and was therefore scheduled for elective lymphatic embolization. Other co-morbidities included a coarctatio aortae, corrected with a coarctectomy and Down syndrome. His treatment included bosentan (endothelin-1 inhibitor), sildenafil, furosemide, spironolactone, prednisolone, inhaled budesonide and inhaled tissue plasminogen activator.

Careful induction by mask with sevoflurane up to maximum 5% was performed. A 22 gauge intravenous line was placed and fentanyl and propofol were given. After tracheal intubation, anesthesia was maintained with sevoflurane with a minimal alveolar concentration of 1.3. Dexamethasone and ondansetron were administered as anti-emetics. Antibiotic prophylaxis consisted of cefazolin and only acetaminophen was given at the end of surgery. The patient was monitored during surgery with ECG, pulse oximetry, capnography and a non-invasive blood pressure. All vital parameters stayed stable during the whole length of the procedure. The procedure consisted of an ultrasound guided puncture of a right iliac lymph node and injection of Lipiodol. After injection, there was drainage in the cisterna chyli and the thoracic duct (Figure 1). The thoracic duct however seemed obstructed. Probably due to earlier cardio-thoracic surgeries. Drainage of Lipiodol occurred through collaterals to the hilus, neck and axillar lymphatic vessels. After saturating the lymphatic vessels, the procedure was stopped. The patient was extubated in the operating room after completion of the surgery and admitted to the post anesthesia care unit (PACU).

¹Department of Anesthesiology, University Hospitals Leuven, Belgium.

*Correspondence: Piet Waelkens, M.D., Department of Anesthesiology, University Hospitals Leuven, Herestraat 49, 3000 Leuven, Belgium; Tel: +32 16 34 48 13; E-mail: piet.waelkens@uzleuven.be

Received date: June 24, 2020; Accepted date: June 25, 2020; Published date: July 15, 2020



This open-access article is distributed under the terms of the Creative Commons Attribution Non-Commercial License (CC BY-NC) (<http://creativecommons.org/licenses/by-nc/4.0/>), which permits reuse, distribution and reproduction of the article, provided that the original work is properly cited and the reuse is restricted to noncommercial purposes. For commercial reuse, contact reprints@pulsus.com

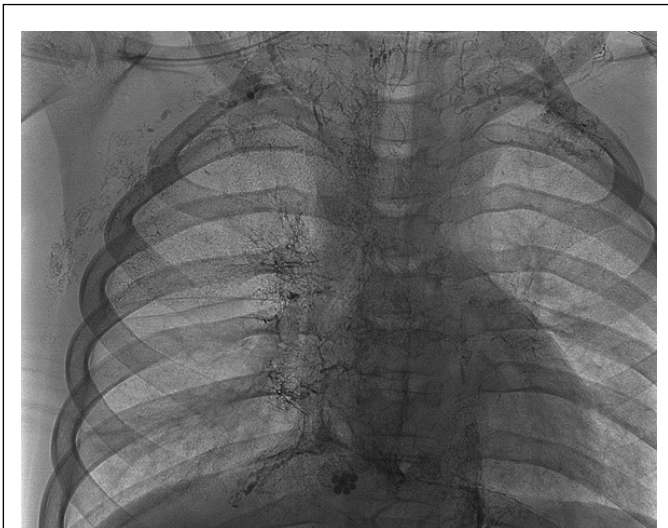

Figure 1) Chest radiograph demonstrating Lipiodol® in peribronchial lymphatic ducts.

Approximately one hour after admission on the PACU, the patient became acutely unresponsive and had a generalized tonic-clonic seizure. The seizure lasted only 30 seconds and faded spontaneously before any benzodiazepines were given. A head computed tomography (CT) scan showed countless hyper densities throughout the brain (Figure 2). When readmitted to the PACU, a new seizure occurred, lasting longer than the first one. Because the patient was desaturating as well, the trachea was intubated with 80 mg of propofol and 30 mg of rocuronium. An arterial and central venous line were placed due to hemodynamic instability and noradrenaline was infused. Levetiracetam was given intravenously and the patient was transferred to the pediatric intensive care unit.

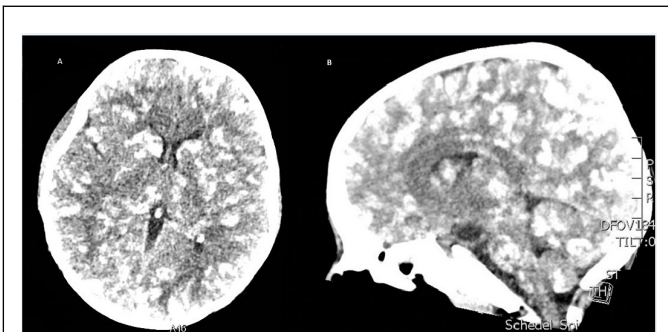


Figure 2) Axial (A) and sagittal (B) CT section post seizure shows numerous hyper densities scattered throughout the brain.

At the intensive care unit, the patient developed a systematic inflammatory response syndrome (SIRS) and multi-organ failure with Lipiodol embolism in the kidneys, liver and lungs. Inhaled NO and hemodynamic support was started. 21 days later, the patient was extubated and listed for heart transplantation. Control CT scan showed improvement of the hyper densities, but no complete remission. Altered neurological status persisted.

DISCUSSION

Percutaneous interventional lymphatic embolization is performed with increasing frequency. It significantly improves symptoms in patients with plastic bronchitis. Cerebral Lipiodol embolization after lymphatic duct embolization is a rare complications and the incidence is unknown because only symptomatic patients undergo neuroimaging. The use of an oil-based contrast agent in children with right-to-left shunting poses a risk for systemic embolization. To minimize this risk, systemic to-pulmonary venous

collateral embolization and temporary fenestration occlusion in these patients are performed [1].

There are multiple case reports describing cerebral Lipiodol embolization after trans arterial chemoembolization for hepatocellular carcinoma [5,6]. Less cases are published after lymphatic embolization for chylothorax [7]. The underlying mechanism for how Lipiodol reaches the brain remains unclear. It involves hepatopulmonary, pulmonary arteriovenous or right-to-left intracardiac shunt. In a case report from Kirschen et al, cerebral embolization occurred due to direct shunting between abnormal lymphatic channels and the pulmonary venous circulation [8]. In a case series of Dori et al [2], a similar case to ours was described. Lipiodol embolism occurred in a post TCPC patient with a complete occlusion of the thoracic duct and no known right-to-left shunts. Numerous lymphovenous connections were seen between lymphatic collaterals and the pulmonary veins, which is possibly the source of the shunting.

In our case, a transoesophageal echocardiography was performed in advance and after the embolization which excluded a patent foramen ovale or any right-to-left shunt. Our hypothesis is that the thoracic duct was absent or occluded due to previous cardio-thoracic surgery. A fistula was probably formed from the thoracic duct to the left atrium. Treatment consisted of mechanical ventilation due to failing oxygenation during the second seizure. Baseline oxygen saturation was 92% in this patient with a Fontan circulation. Only supportive treatment can be given. Optimization of the TCPC pathway and cardiovascular circulation should be considered as an important part of the treatment as well.

Previous reports describe that the onset of symptoms occurs less than six hours from exposure in 85% of cases [4]. The amount of contrast that reaches the brain may also influence the occurrence. The risk increases when more than 20 mL of Lipiodol is used. The recommended maximum dose of ethiodized oil is 0.25 mL.kg-1 [9]. Poor neurological outcome has been reported in previous cases up to 20%.

Cerebral Lipiodol embolization is a rare but severe complication after lymphatic interventional radiography. It should be considered when neurological symptoms occurs in the postoperative period. Prolonged PACU admission is recommended. Neuroimaging should be performed without any delay. Supportive care is the mainstay treatment for cerebral Lipiodol embolization. Cardiac catheterization could be performed prior to the procedure in patients with congenital heart disease to exclude abnormal shunting.

ACKNOWLEDGEMENTS

Piet Waelkens, MD, Sofian Bouneb, MD and Johan Vandommele, MD. Contribution: These authors helped reviewing the final manuscript, provided permission to publish the manuscript, made substantial contributions by revising the manuscript critically, made final approval for the submitted manuscript, and endorsed the conclusion.

FINANCIAL DISCLOSURES

None

CONFLICTS OF INTEREST

Piet Waelkens, Sofian Bouneb and Johan Vandommele have no conflicts of interest to declare.

REFERENCES

1. Biko DM, Dori Y, Savoca M, et al. Pediatric pulmonary lymphatic flow disorders: Diagnosis and management. *Paediatr Respir Rev*. 2019.
2. Dori Y, Keller MS, Rome JJ, et al. Percutaneous lymphatic embolization of abnormal pulmonary lymphatic flow as treatment of plastic bronchitis in patients with congenital heart disease. *Circulation*. 2016; 133(12):1160-70.
3. Hara H, Mihara M and Yamamoto M. Therapeutic Lymphangiography for Traumatic Chylothorax. *J Vasc Surg Venous Lymphat Disord*. 2018; 6 (2):237-40.

Cerebral Lipiodol® Embolism after interventional lymphatic embolization: a case report

4. Chu HJ, Lee CW, Yeh SJ et al. Cerebral Lipiodol embolism in hepatocellular carcinoma patients treated with transarterial embolization/chemoembolization. *PLoS One*. 2015;10 (6).
 5. Yoo K.M, Yoo, B.G, Kim K.S et al. Cerebral lipiodol embolism during transcatheter arterial chemoembolization. *Neurology*. 2004; 63:181-83.
 6. Ishimaru H, Morikawa M, Sakugawa T, et al. Cerebral Lipiodol Embolism Related to a Vascular Lake During Chemoembolization in Hepatocellular Carcinoma: A Case Report and Review of the Literature. *World J Gastroenterol*. 2018; 24(37):4291-96.
 7. Geeroms B, Demaerel Ph, Wauters J et al. Devastating cerebral Lipiodol® embolization related to therapeutic lymphangiography for refractory chylothorax in a patient with Behçet's disease. *Vasa*. 2018; 47(5): 427-29.
 8. Kirschen MP, Dori Y, Irkin M et al. Cerebral Lipiodol Embolism after lymphatic embolization for plastic bronchitis. *J Pediatr*. 2016; 176: 200-203.
 9. Sheybani A, Gaba RC and Minocha J. Cerebral embolization of ethiodized oil following intranodal lymphangiography. *Semin Intervent Radiol*. 2015; 32 (1):10-13.
-
-