

Use of external fixation to simplify postoperative care of free flap to the leg

Patrick G Harris MD CM FRCSC, John F Mosher MD CM FACS, Jon B Loftus MD
Hand Surgery Service, Department of Orthopedic Surgery, SUNY Health Science Center at Syracuse,
New York, USA

PG Harris, JF Mosher, JB Loftus. Use of external fixation to simplify postoperative care of free flap to the leg. *Can J Plast Surg* 1994;2(3):133-134. External fixation is recommended instead of the combination of a bulky dressing and a posterior splint to facilitate postoperative care of free flap surgery to the lower extremity. Balanced suspension of external skeletal fixation allows adequate elevation, minimal dressing, unobstructed view of the flap for monitoring and freedom from pressure points. The slightly longer operative time required is justified by the easier postoperative care. No complications have been associated with the use of external fixation.

Key Words: *External fixation, Free flap, Postoperative complication*

Recours à une fixation externe pour simplifier les soins post-opératoires d'un lambeau libre à la jambe

La fixation externe est recommandée plutôt que la combinaison d'un pansement encombrant et d'une attelle postérieure pour faciliter les soins post-opératoires dans la chirurgie pour lambeau libre au niveau de la jambe. L'installation d'une fixation externe équilibrée permet une élévation adéquate, un pansement minimal et une bonne visibilité du lambeau aux fins d'observation et le tout, en l'absence de points de pression. La durée légèrement plus longue de la chirurgie est justifiée par les soins post-opératoires rendus plus faciles. Aucune complication n'a été associée au recours à telle une fixation externe.

The postoperative regimen for free flap coverage of a wound of the distal third of the leg requires immobilization of the ankle. This is performed for two reasons. First it prevents motion around the flap thereby protecting the vascular anastomosis. It also serves to prevent an equinus deformity of the ankle by keeping the foot at 90°. Clinically these requirements have been satisfied with a bulky protective dressing on the leg and placing a posterior splint across the ankle maintaining it at 90°. The leg is elevated on pillows to facilitate venous drainage and prevent edema formation. Several problems have been encountered with this regimen. Practically, the dressing can be obtrusive to at least part of the flap even if a window has been made in the dressing. The leg also has a tendency to slip in the splint leaving the foot in some plantar flexion. This slippage of the splint potentially can cause a pressure sore on the posterior heel (Figure 1). Keeping the extremity elevated on pillows is also difficult, particularly in the multiply traumatized patient, or unstable as the patient moves in bed to find a more comfortable position. Furthermore, the bulky dressing, especially in cases of skin grafted muscle flaps, tends to become messy.

To correct these problems, an external fixator has been extended across the ankle. Initially this was done only if a fixator was already in place to stabilize the tibia fracture. This

soon evolved into using an external fixator even in the face of no bony injury for no other purpose than immobilizing the ankle. The external fixator keeps the ankle in the appropriate position thereby preventing an equinus deformity. There is also no posterior plaster of paris or fibreglass splint that could potentially cause a pressure sore. The leg can be suspended with balance traction via the external fixator keeping elevation constant and comfortable (Figure 2). This technique also obviates a need for a bulky dressing and the entire flap is visible for complete monitoring.

Technically, the application of the external fixator requires about 30 more minutes of operating time, usually at the end of the free flap procedure. Different techniques and systems can be used. To control ankle position there are essentially two formations of external skeletal fixation (ESF): tibio-metatarsal and tibio-calcaneal-metatarsal. The tibeal element is composed of two 4 mm half pins or attachment to the tibeal ESF already in position. The metatarsal element is either two 3 mm half pins inserted obliquely into the proximal first metatarsal, or one inserted into the base of the first metatarsal and one obliquely into the base of the fifth. If there is an element of heel varus, such as in more chronic cases, the calcaneus is transfixated with a 4 mm pin. The ankle is placed in a neutral position and the pins are connected by bars. If there is a fixed contraction (equinus or varus), serial connections can be performed with the ESF. Postoperatively the suspension device can be attached to the fixator with two ropes, one distally and one proximally, preferably through a

Correspondence and reprints: Dr John F Mosher, 550 Harrison Center, Suite 100, Syracuse, NY 13202, USA. Telephone (315) 472-2015, Fax (315) 472-2211.

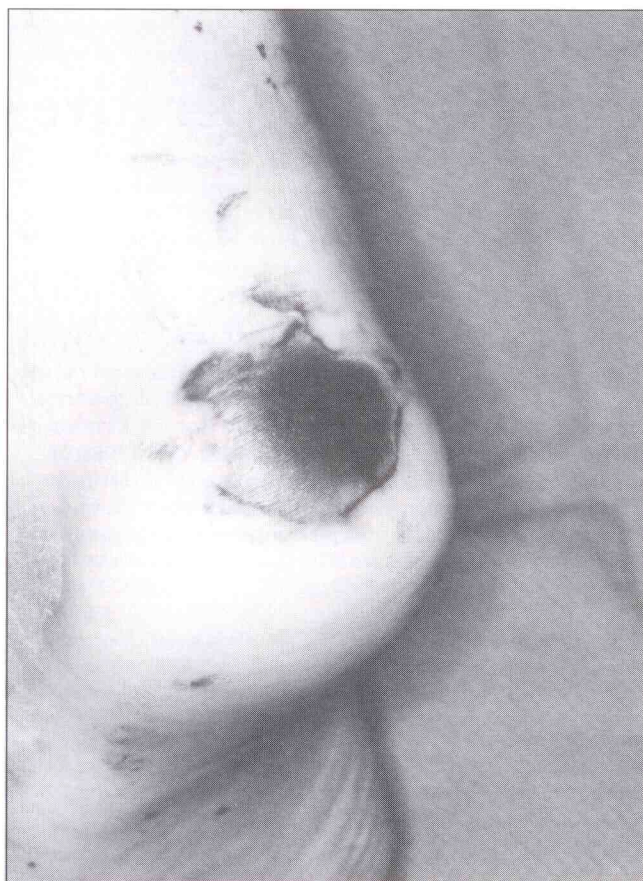


Figure 1) Pressure sore on heel

balanced pulley system. Pin care is not required except a small, dry dressing should be placed around them to prevent skin movement on the pin.

Monitoring of the flap is also easier as it can be completely visualized. Dressing changes are not required and pressure sores are prevented. The external fixator is usually removed at the bedside or in the out-patient clinic follow-up in one to three weeks. No anaesthesia or sedation is required for removal of the external fixator. The pinholes are just dressed with small, dry dressings and will close in a few days.

In theory, infection can be a complication in use of an

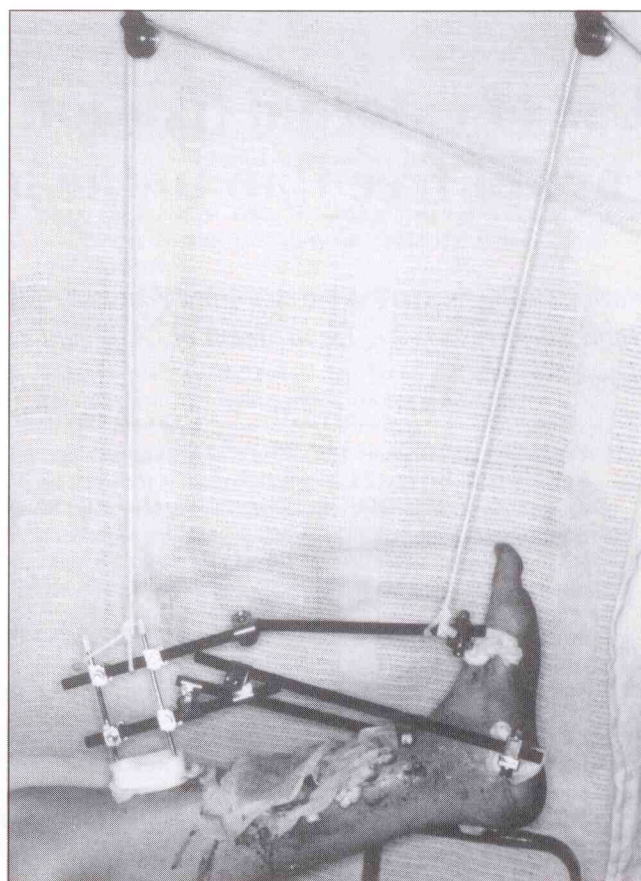


Figure 2) Balance suspension with external fixation

external fixator but as the time of its use is short, this is unlikely and has not been encountered. Although patients might be slightly apprehensive about the use of the external skeletal fixator, they appear to be more comfortable than with the use of bulky dressings and splints.

CONCLUSION

The use of external fixation instead of bulky dressings and splints to immobilize the leg and foot has proven to be worthwhile and simplifies the postoperative care of patients with free-flaps to the lower extremity.